

Propionebacterium acnes associated with inflammation in benign prostatic hyperplasia



Syakri Syahrir¹, Mochammad Hatta², Warsinggih Warsinggih³, Rosdiana Nasir⁴, Dianawaty Amiruddin⁵,
Ressy Dwiyaniti⁶

Urology Division, Department of Surgery, Medical Faculty Hasanudddin University, Indonesia¹,
Molecular Biology and Immunology Laboratory, Medical Faculty Hasanudddin University, Makassar,
Indonesia²,

Department of Surgery, Medical Faculty Hasanudddin University. Indonesia³,

Department of Biochemistry, Medical Faculty Hasanudddin University. Makassar, Indonesia⁴,

Department of Parasitology, Medical Faculty Hasanudddin University, Makassar⁵,

Department of Microbiology, Faculty of Medicine, Tadulako University, Palu, Indonesia⁶

ABSTRACT— Benign Prostatic Hyperplasia (BPH) is the most frequent disease in elderly men, but the exact pathogenic mechanism of the disease is still largely unknown. The etiology of infection that induces inflammation plays an important role in the pathomechanisms of BPH. *Propionebacterium acnes* (*P. acnes*) is a microorganism that is often found in prostate tissues. We investigate the frequency of *P. acnes* and its relationship with prostate inflammation in patients with BPH. Cross-sectional research was conducted in several hospitals in Indonesia. A total of 50 BPH patients undergoes the procedure of transurethral resection of prostate, DNA examination of *P.acnes* with Multiplex Touchdown PCR, and the examination of IL-6 and IL-8 by ELISA. Of the 50 patients underwent the examination of the PCR, 14 (28%) were positive *P. acnes* and 36 (72%) were negative *P. acnes*. Histopathological examination results revealed that all patients with BPH and prostatitis (100%) show the increasing level of IL-6 with an average of 490.5 ± 242.2 pg/ml while level of IL-8 had an average of 118.3 ± 50.4 pg/ml. With statistical tests, it was obtained that there was a significant association between *P. acnes* and the increased level of IL-6 and IL-8. The present study provide further evidence for the role of *P.acnes* in prostate inflammation. *P. acnes* can be a contributing agent by triggering cell proliferation.

Keywords— Benign prostatic hyperplasia, prostatitis, *P. acnes*, interleukin-6, interleukin-8.

1. INTRODUCTION

Benign Prostatic Hyperplasia (BPH) is described as an increase in the total number of stromal and epithelial cells in the prostate gland. BPH is associated with the symptoms of the lower tract that impact the quality of one's life and interfere with daily activities. BPH is a chronic disease most commonly found in elderly male populations [1,2].

Aging and androgen hormones play a role in the development of BPH but its pathogenesis is still unclear. The obtained data shows that the inflammatory factor has an important role in the pathogenesis of BPH which can worsen the clinical symptoms [3,4].

The origin of chronic prostate inflammation is still unclear and may occur due to multiple stimuli working simultaneously. Different sources of prostatic inflammation have been proposed including bacterial infections (*Escherichia coli*), viruses (*human papillomavirus*, *human herpes simplex virus* and *cytomegalovirus*), sexually transmitted organisms (*Neisseria Gonorrhoeae*, *Treponema Pallidum*, *Chlamydia trachomatis*, and

Trichomonas Vaginalis), dietary factors, hormones, autoimmune response, and urine reflux. Although the prevalence of inflammatory prostate or prostatitis is high, the exact cause is unclear [4,5].

Some bacteria that are sometimes found in the prostate include species from *Escherichia*, *Chlamydia*, *Neisseria*, and *Staphylococcus* genus. Recently, it is also reported that *Propionibacterium acnes* (*P. acnes*) is detected with high frequencies in prostate tissues of patients with prostatitis and prostate carcinoma [6,7].

Anaerobic positive gram bacteria *P. acnes* can be found in the sebaceous follicles of human skin. *P. acnes* is one of the pathophysiological factors which play a role in the formation of acne vulgaris [8]. *P. acnes* also identified has immunostimulatory activity. Other study indicates that *P. acnes* is not found in healthy prostate tissues but it is more often found in prostate cancer [7]. Cell culture research illustrates that *P. acnes* poses a strong inflammatory response to the prostate cells and initiates a cellular transformation [9,10].

The purpose of this research is to investigate the role of *P. acnes*, IL-6 and IL-8 in benign prostatic hyperplasia with inflammation.

2. MATERIAL AND METHODS

All men patients who were diagnosed with BPH carried out the procedure of transurethral resection of the prostate. Prostate tissue samples went through histopathological examination with HE (hematoxylin-eosin) staining, Polymerase Chain Reaction (PCR) for detect DNA *P. acnes* and IL-6 and IL-8 in ELISA procedure. Of 50 samples, the result of histopathology is BPH with prostatitis.

2.1 Detection of *P. acnes* DNA

Prostate tissue samples were drawn using transurethral resection procedure. Samples were stored at -70° C and then sample transferred to laboratory for analysis. The DNA from tissue was extract in a 25 µL reaction mixture containing 1 µL silica-guanidinium isothiocyanate purified previous method [11,12]. Detection of *P. acnes* gene by using specific primer of PA-F 5'-AAGCGTGAGTGACGCTAATGGGTA-3' and PA-R 5'-CCACCATAACGTGCTGGCAACAGT-3'. PCR reaction was performed for 40 cycles at 94°C for 30 s, 54°C for 60 s, and 72°C for 1 min, followed by an extension step of 72°C for 5 min using The CFX Connect system, Biorad Laboratories instrument [13].

2.2 Electrophoresis

Every 10 µl of the amplification product was mixed with 5 µl of loading solution. Once well-blended, each one was inserted into the 2% agarose gel wells that are immersed in the tank containing the TBE buffer. Furthermore, electrophoresis was run for 1 hour with a constant voltage of 75 volts. After 1 hour, the electrophoresis was stopped and a gel lifted to be observed under UV rays. The result was categorized as positive if the DNA band exists and negative if there is no DNA band in the gel [13].

2.3 Measurement IL-6 and IL-8 soluble secretion

To measure the capability of *P. acnes* modulating proinflammatory mediators, secreted IL-6 and IL-8 were measured by ELISA. The samples were analyzed using IL-6 and IL-8 kits (LSBio lifespan Biosciences, Inc, USA) according to the manufacturer's instructions. The concentration was determined by measuring the optical density at wave length of 450 nm on a spectrophotometer (ELISA reader Biorad, USA).

2.4 Statistical analysis

All analyses and graphics were performed using IBM SPSS Statistics software (SPSS). Mann-Whitney and Independent t test were used for comparison. All results are presented as mean \pm SD. A two-sided $p < 0.05$ defined as statistical significance

3. RESULTS

3.1 Isolation of *P. acnes* from prostate tissue samples

In this study, the researchers obtained 50 BPH patients undergoing a *trans-urethral resection of the prostate* (TURP) procedure. Previously, patients will be excluded from the study if they meet the exclusion criteria including symptoms of acute prostatitis, prostate cancer and previous prostate surgery. Prior to the procedure of TURP, the subjects underwent blood sampling for the examination of IL-6 and IL-8 and with antimicrobial prophylaxis given. At the time of TURP, researcher conducted the extraction of “inner” tissue specimen randomly with approximately 1-2 gr and through sterile way with the resectoscope and was stored in the L6 tube then was transferred to the laboratory to further perform histopathology examination and PCR. A PCR examination was established to detect *P. acnes* in prostate tissue sample. The characteristics of the study sample are illustrated in Table 1. PCR revealed the presence of *P. acnes* in 14 (28%) samples of BPH with prostatitis. The subject age of study was 68.2 ± 8.9 years old ranged from 51-85 years old patients. The sample's prostate size is around $64,2 \pm 31,4$ mm. The level of IL-6 increases with an average of 490.5 ± 242.2 pg/ml while level of IL-8 has an average of 118.3 ± 50.4 pg/ml.

Variable	N	Mean \pm SD
Age (years)	50	68.2 ± 8.9
Volume Prostate (mm)	46	$64,2 \pm 31,4$
<i>P.acnes</i> (n,%)		
Positive	14	28,0
Negative	36	72,0
Mediator Proinflammatory		
IL-6 (pg/ml)	50	$490,5 \pm 242,5$
IL-8 (pg/ml)	50	$118,3 \pm 50,5$

Table 1. Characteristics of men with benign prostatic hyperplasia

3.2 The association of *P. acnes*, IL-6 and IL-8 soluble

In Table 2, it shows the association of proinflammatory cytokine IL-6 and IL-8 with *P. acnes* bacteria. The level of IL-6 is significantly higher in positive bacteria (mean 790.6 ± 70.9 pg/ml) than in negative bacteria (mean 373.7 ± 173.8 pg/ml). This indicates a significant association between the *P. acnes* bacteria and high IL-6 levels ($p < 0.001$). Similarly, the level of IL-8 is significantly higher in positive bacteria (mean 175.6 ± 15.1 pg/ml) than in negative bacteria (mean 96.0 ± 40.6 pg/ml). This indicates a significant association between the bacteria *P. acnes* and high IL-8 levels ($p < 0.001$).

Cytokine	<i>P. acnes</i>	N	Mean	SD	P
IL-6	Positive	14	790.6	70.9	<0.001
	Negative	36	373.7	173.8	
IL-8	Positive	14	175.6	15.1	<0.001
	Negative	36	96.0	40.6	

Table 2. Association *P. acnes* with IL-6 and IL-8 in benign prostatic hyperplasia

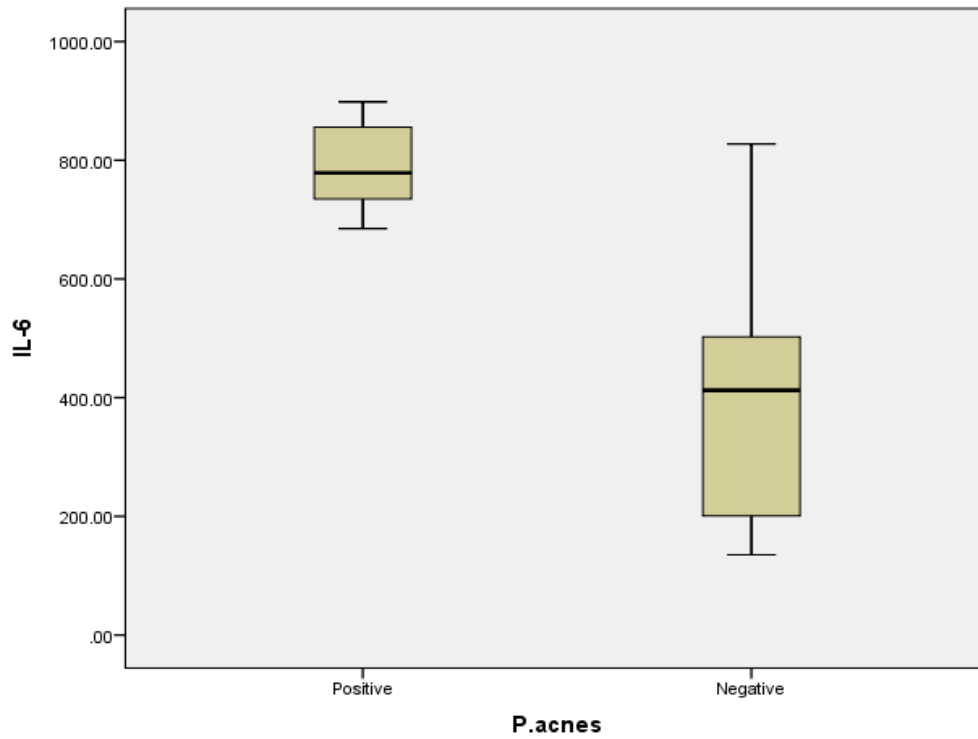


Figure 1. Level of IL-6 from prostate cell with and without infected *P. acnes*

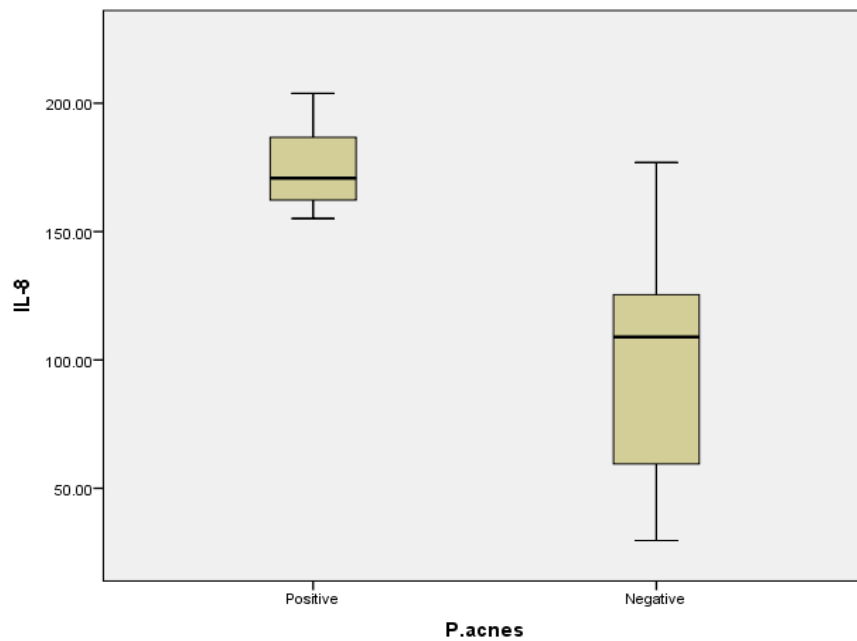


Figure 2. Level of IL-8 from prostate cell with and without infected *P. acnes*

4. DISCUSSION

The number of subjects with positive *P. acnes* in this study was 14 (28%) and the number of negative *P. acnes* was 36 (72%) samples. Previous study reported that there were *P. acnes* as much as 35% in the primary isolate of prostate cancer. Furthermore, similarly also reported that *P. acnes* as the predominant microorganism was found in prostate tissues after the transurethral resection of the prostate of BPH patients [10,14]. All of the subjects (100%) in this study are benign prostatic hyperplasia with chronic prostatitis. A Study on the prevalence of inflammation and benign prostatic hyperplasia in Asians and Caucasians found more than 70% of inflammation existed on autopsy [3]. It can be considered that inflammation of the prostate is caused by multifactor. As it is known that various bacteria, as well as viruses and fungi, have been found in the prostate but no study has reported that it is associated with asymptomatic prostate inflammation [15]. The association between BPH and intraprostatic inflammation was first proposed based on the histological existence of hyperplastic nodules and chronic inflammatory infiltrates in a high proportion of BPH tissues [16]. Thus, chronic inflammation is believed to support the process of fibromuscular growth in BPH

4.1 *P. acnes* induces up-regulation cytokine IL-6 and IL-8

Interleukin 6 (IL-6) is a multi-functional cytokine that is produced by a range of cells and plays a central role in host defenses mechanisms. It is now known that IL-6 is a pleiotropic cytokine that is produced by a variety of cells and acts on a wide range of tissues secreting of growth inducing, growth inhibitory and differentiation inducing effects, depending on the nature of the target cells [17]. The rate of IL-6 in this study was 490.5 ± 242.2 pg/ml. In normal homeostatic conditions, IL-6 levels are usually low. However, the response to a stimulus, e.g. inflammation, causes the cells to produce IL-6. IL-6 is a potent inflammatory cytokine that exhibits functional pleiotropy in numerous cell types. It is released not only by inflammatory cells, but also prostate stromal cells and prostate cancer cells [18].

Epidemiological studies were found an increase in IL-6 in BPH patients under the age of 65. Evidence suggests that IL-6 also contributes to the progressivity of prostate cancer. Other study, reported an increase in IL-6 levels in patients with Hormone refractory prostate cancer compared to normal control [19]. In vitro *P. acnes* induces the secretion of IL-6 and IL-8. IL-8 secretions are mediated through the TLR-2 [20]. Some studies have proved that *P. acnes* can stimulate monocytes and endothelial cells to secrete proinflammatory cytokines through TLR-2 [21]. Even TLR-4 and TLR-9 are influential in the immune modulatory effect by *P. acnes* [22]. This study found a significant positive association between *P. acnes* and high levels of IL-6. Based on this result, it can be assumed that *P. acnes* triggers the stimulation of immune response and can induce the production of proinflammatory cytokine IL-6. Similarly, in vitro studies showed that *P. acnes* induces the increase secretion of IL-6 and IL-8 in prostate epithelium cells [20]. Although the average IL-8 count in this study was 118.3 ± 50.5 , which is lower than the average rate of IL-6 but this study found a significant positive association between *P. acnes* and increased levels of IL-8. IL-8 is a proinflammatory cytokine that is secreted by the prostate epithelium cells involved in the chemotaxis of the leucocytes. Elevated levels of IL-8 were found in the prostate tissue of BPH patients and were extremely high in BPH patients with chronic prostatitis. The results of this research support theories suggesting that IL-8 plays an important role in the development of the prostate and plays a role in prostate growth mechanisms that are part of tissue remodeling or regeneration in response to inflammation [23,24].

The secretion of IL-6 and IL-8 is the center of recruitment and differentiation of macrophages and neutrophil in inflammatory tissues [25]. Other study, reported that *P. acnes* induces an increase in the expression of IL-8 in endothelial cells of hair follicles related to epidermal hyperplasia and follicular hyperkeratosis on acne

vulgaris and psoriasis [26]. Similarly, the research was indicated that the prostate epithelium significantly contributes to the increase in the expression of IL-6 and IL-8 locally when it was infected with *P. acnes* and provides side effects by increasing proliferation and angiogenesis activities with autocrine and or endocrine mechanisms [20,25].

5. CONCLUSION

This study provides further evidence of the role of *P. acnes* in benign prostatic hyperplasia (BPH) by revealing that men with BPH will likely be infected by *P. acnes* Prostate compared to men without this illness. Further cell-based experiments indicate that *P. acnes* can be a contributing agent by triggering cell proliferation and secretion of IL-6 and IL-8. A prospective study is required to prove these findings so that the results will have an impact to prevent disease progressivity and to develop therapeutic strategies to implement in the future.

6. Conflict of interest

The authors have nothing to disclose

7. Acknowledgment

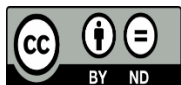
We thank all of staff and laboratory technician in Molecular Biology and Immunology Laboratory, Faculty of Medicine, Hasanuddin University, Makassar, Indonesia for their excellent laboratory examination in this study.

8. References

- [1] Briganti, A., Capitanio, U., Suardi N, Gallina A, Salonia A, Bianchi M, Tutolo M, Di Girolamo V, Guazzoni G, Rigatti P, and Montorsi F. (2009). Benign Prostatic Hyperplasia and Its Aetiologies. *Eur Urol Suppl*,8(13), pp.865–871.
- [2] Ribal, M. J. (2013). The Link Between Benign Prostatic Hyperplasia and Inflammation. *European Urology Supplements*, 12(5), pp.103–109.
- [3] Zlotta, A. R., Egawa, S., Pushkar, D., Govorov, A., Kimura, T., Kido, M., Takahashi, H., Kuk, C., Kovylyna, M., Aldaoud, N., Fleshner, N., Finelli, A., Klotz, L., Lockwood, G., Sykes, J., and Kwast, T. van der. (2014). Prevalence of Inflammation and Benign Prostatic Hyperplasia on Autopsy in Asian and Caucasian Men. *European Urology*, 66(4), pp.619–622.
- [4] Gandaglia, G., Briganti, A., Gontero, P., Mondaini, N., Novara, G., Salonia, A., Sciarra, A., and Montorsi F. (2013). The role of chronic prostatic inflammation in the pathogenesis and progression of benign prostatic hyperplasia (BPH). *BJU International*, 112(4), pp.432–441.
- [5] De Nunzio, C., Presicce, F., & Tubaro, A. (2016). Inflammatory mediators in the development and progression of benign prostatic hyperplasia. *Nature Reviews Urology*, 13(10), pp.613–626.
- [6] Alexeyev, O., Bergh, J., Marklund, I., Thellenberg-Karlsson, C., Wiklund, F., Grönberg, H., Bergh, A., and Elgh F. (2006). Association between the presence of bacterial 16S RNA in prostate specimens taken during

- transurethral resection of prostate and subsequent risk of prostate cancer (Sweden). *Cancer Causes & Control*, 17(9), pp.1127–1133.
- [7] Fassi Fehri, L., Mak, T. N., Laube, B., Brinkmann, V., Ogilvie, L. A., Mollenkopf, H., Lein M, Schmidt T, Meyer TF. and Brüggemann, H. (2011). Prevalence of *Propionibacterium acnes* in diseased prostates and its inflammatory and transforming activity on prostate epithelial cells. *International Journal of Medical Microbiology*, 301(1), pp.69–78.
- [8] Grice, E. A., and Segre, J. A. (2011). The skin microbiome. *Nature Reviews Microbiology*, 9(4), pp.244–253
- [9] Bae, Y., Ito, T., Iida, T., Uchida, K., Sekine, M., Nakajima, Y., Kumagai, J., Yokoyama, T., Kawachi, H., Akashi, T., and Eishi Y. (2014). Intracellular *propionibacterium acnes* infection in glandular epithelium and stromal macrophages of the prostate with or without cancer. *PLoS One*, 9(2), pp.1–11
- [10] Cohen, R., Shannon, B., Mcneal, J., Shannon, T., and Garrett, K. (2005) *Propionibacterium acnes* associated with inflammation in radical prostatectomy specimens: A possible link to cancer evolution? *The Journal of Urology*, 173(6), pp.1969–1974.
- [11] Hatta, M., and Smits HL. (2007). Detection of *Salmonella typhi* by nested polymerase chain reaction in blood, urine, and stool samples. *Am J Trop Med Hyg*, 76(1), pp.139–143.
- [12] Hatta, M., Sultan, A. R., Tandirogang, N., Masjudi, & Yadi. (2010). Detection and identification of mycobacteria in sputum from suspected tuberculosis patients. *BMC Research Notes*, 3(1), pp.72-78
- [13] Barnard, E., Nagy, I., Hunyadkürti, J., Patrick, S., and McDowell, A. (2015). Multiplex touchdown PCR for rapid typing of the opportunistic pathogen *Propionibacterium acnes*. *Journal of Clinical Microbiology*, 53(4), pp.1149–1155
- [14] Alexeyev, O., Olsson, J., & Elgh, F. (2009). Is There Evidence for a Role of *Propionibacterium acnes* in Prostatic Disease? *Urology*, 73(2), pp.220–224
- [15] Sciarra A, Di Silverio F, Salciccia S, Autran Gomez AM, Gentilucci A. and Gentile V. (2007). Inflammation and Chronic Prostatic Diseases: Evidence for a Link?. *Eur Urol*, 52(4), pp.964–972.
- [16] Sciarra, A., Mariotti, G., Salciccia, S., Gomez, A. A., Monti, S., Toscano, V., and Di Silverio, F. (2008). Prostate growth and inflammation. *The Journal of Steroid Biochemistry and Molecular Biology*, 108(3–5), pp.254–260.
- [17] Hirano, T., Akira, S., Taga, T., and Kishimoto, T. (1990). Biological and clinical aspects of interleukin 6. *Immunology Today*, 1(12), pp.443–449.

- [18] Hobisch, A., Rogatsch, H., Hittmair, A., Fuchs, D., Bartsch, G., Klocker, H., Bartsch, G., and Culig, Z., (2000). Immunohistochemical localization of interleukin-6 and its receptor in benign, premalignant and malignant prostate tissue. *The Journal of Pathology*, 191(3), pp.239–244.
- [19] Drachenberg, D. E., Elgamal, A.-A. A., Rowbotham, R., Peterson, M., and Murphy, G. P. (1999). Circulating levels of interleukin-6 in patients with hormone refractory prostate cancer. *The Prostate*, 41(2), pp.127–133.
- [20] Drott, JB, Alexeyev, O., Bergström, P., Elgh, F., and Olsson J. Propionibacterium acnes infection induces upregulation of inflammatory genes and cytokine secretion in prostate epithelial cells. *BMC Microbiol.* 2010;10:126.
- [21] Vowels, BR., Yang, S., Leyden, JJ., (1995). Induction of proinflammatory cytokines by a soluble factor of Propionibacterium acnes: Implications for chronic inflammatory acne. *Infect Immun*, 63(8), pp.3158–3165.
- [22] Jugeau, S., Tenaud, I., Knol, AC., Jarrousse, V., Quereux, G., Khammari, A., and Dreno, B., (2005). Induction of toll-like receptors by Propionibacterium acnes. *Br J Dermatol*, 153(6), pp.1105–1113.
- [23] Castro, P., Xia, C., Gomez, L., Lamb, DJ., and Ittmann, M. (2004). Interleukin-8 expression is increased in senescent prostatic epithelial cells and promotes the development of benign prostatic hyperplasia. *Prostate*, 60(2), pp.153–159.
- [24] Liu, L., Li, Q., Han, P., Li, X., Zeng, H., Zhu, Y., and Wei, Q., (2009). Evaluation of Interleukin-8 in Expressed Prostatic Secretion as a Reliable Biomarker of Inflammation in Benign Prostatic Hyperplasia. *Urology*, 74(2), pp.340–344.
- [25] Hébert, C. A., & Baker, J. B. (1993). Interleukin-8: A Review. *Cancer Investigation*, 11(6), pp.743–750.
- [26] Abd El All, H. S., Shoukry, N. S., El Maged, R. A., and Ayada, M. M. (2007). Immunohistochemical expression of interleukin 8 in skin biopsies from patients with inflammatory acne vulgaris. *Diagnostic Pathology*, 2(1), pp.4–9.



This work is licensed under a Creative Commons Attribution Non-Commercial 4.0 International License.